



Effect of adding Pomegranate Seed Pomace to the feed to reduce pathological histological changes in the liver of broiler chickens infected with *Aspergillus niger* toxins

Hajir issa yousif alawsi¹, Mohanad Fadhl Hussain Al- Musodi¹, Zeinab A. M. Al-tememe¹

Abstract

The study aimed to isolate the *Aspergillus niger* from pelleted poultry feed, and to study its production of mycotoxins in a number of regions of Karbala Province, represented by (Tuwairij, Qantara Al-Salam, Al-Tahadi neighborhood and Fariha) and to characterize it morphologically and partially during 20/9/2025. The isolation and diagnosis of the pathogen were completed based on their morphological, molecular and Sequencing revealed *A. niger* isolate that have been registered at the GeneBank, The world record for Iraqi isolation according to the entry numbers PX569964.1. In comparison to the control group the mycotoxin infected poultry revealed histopathological lesions particularly liver showing necrosis, vascular congestion, proliferation of inflammatory cells and mild to severe hepatocellular degeneration. The liver displayed slight hepatocellular degenerative changes after treating poultry with pomegranate seed Pomace with 2%. Administering nystatin, at a concentration of 1.25 g/kg of feed, to poultry previously treated with mycotoxins resulted in mild degenerative changes in liver cells. The Nystatin 1.25g/kg + Pomegranate Seed Pomace to poultry previously treated with mycotoxin show the highest level of histological improvement was seen in this group. The architecture was nearly typical, with little cellular deterioration and no necrosis.

¹ (Department of Animal Production - Faculty of Agriculture - University of Kerbala-Iraq)

*hajir.i@s.uokerbala.edu.iq, Mohanad.fadhl@uokerbala.edu.iq, zainab.mohammed@uokerbala.edu.iq

Keyword: *A. niger*, poultry, pellet feed, PCR, pomegranate seed, Nystatin.

Introduction

Proper nutrition is a cornerstone of modern poultry production, with feed accounting for more than 60% of total production costs, often exceeding 60% (D’Mello, 2000; Al-Jebory et al., 2024). Reports from the Food and Agriculture Organization of the United Nations (FAOSTAT, 2012; Ajafar et al., 2024) indicate that selecting an appropriate diet does not merely provide energy and essential nutrients for growth, but also supports bird health, enhances immune function, and maximizes productive efficiency (Salman et al., 2024&2025). Pellet feed has emerged as one of the most important innovations in poultry feeding systems due to its significant advantages over mash diets. This compressed feed form improves palatability, reduces feed wastage, and enhances growth performance and feed conversion ratio (FCR) (Ghasemi *et al.*, 2021; Arkan et al., 2025). Furthermore, according to FAOSTAT (2021), the thermal processing involved in pelleting improves starch and protein digestibility and reduces microbial contamination, thereby enhancing feed safety and supporting flock health. Despite these advantages, poultry feeds remain susceptible to fungal contamination and the production of mycotoxins, which represent one of the most serious challenges facing the global poultry industry due to their substantial economic losses and detrimental effects on bird health. Mycotoxins are secondary metabolites produced by certain fungal species as a defense mechanism, subsequently entering the food chain through contaminated feed. Fungi belonging to the genus *Aspergillus* are among the primary causative agents of mycotoxicosis in poultry, posing a major challenge to the livestock production sector worldwide. These fungi are capable of producing a wide range of secondary toxic metabolites, most notably aflatoxins, which are considered among the most hazardous natural contaminants in feed (D’Mello and Macdonald, 1997, Al-Musodi et al. 2025). Warm and humid storage conditions provide an ideal environment for fungal growth and proliferation, and pelleted feed has been identified as one of the potential substrates conducive to fungal contamination, making it a significant source of aflatoxin exposure in poultry flocks. Upon ingestion of contaminated feed, mycotoxins induce widespread pathological effects on vital organs. The liver is the primary target organ and the most severely affected, as mycotoxins cause hepatocellular necrosis, fibrosis, and enlargement, leading to impaired hepatic function (Kandhare *et al.*, 2017). This damage reduces the bird’s ability to metabolize toxins, resulting in increased systemic accumulation (Bennett and Klich, 2003). Moreover, mycotoxins significantly suppress the immune system, increasing susceptibility to bacterial, viral, and parasitic infections (Ramos et al., 1996). The toxic effects are not limited to the liver but extend to the kidneys, spleen, and other lymphoid organs, ultimately impairing overall performance, reducing growth rate and feed efficiency, and increasing mortality rates. Pomegranate (*Punica granatum L.*) is an ancient fruit widely used in traditional medicine (Çam and İçyer, 2014). It possesses potential anticancer, antioxidant, antimicrobial, antimutagenic, and antiviral properties (Negi *et al.*, 2003). Pomegranate fruits are rich in vitamin C, anthocyanins, hydrolyzable tannins, and organic acids, which have contributed to their extensive use in traditional therapeutic applications (Malik *et al.*, 2005). The detrimental effects associated with the fungal species under investigation not only lead to marked reductions in productive performance and growth rates but also pose a threat to food safety through the transfer of toxins into animal-derived products such as meat and eggs. The primary objective of this study is to evaluate the efficacy of dietary Pomegranate Seed Pomace (PSP) supplementation in mitigating the hepatotoxic effects and histopathological lesions induced by *Aspergillus niger* toxins in broiler chickens.

Materials and methods

Isolation:

Billet feed samples were randomly collected from different regions in Karbala Province, represented by the regions of (Tuwairij, Qantara Al-Salam, Al-Tahadi neighborhood and Fariha). On 20/9/2025, a number of sites were randomly identified in these regions, including poultry feed storage halls and chicken markets. Independent 200 g samples were collected per site, transported in polyethylene bags, and homogenized to ensure representativeness. For fungal isolation, 0.5 g sub-samples were uniformly distributed onto 9 cm sterile Petri dishes containing Potato Dextrose Agar (PDA). This medium was prepared by dissolving 39 g of PDA powder in one liter of distilled water, followed by autoclave sterilization at 121°C and 15 psi for 20 minutes. To ensure a sterile growth environment and inhibit bacterial interference, 250 mg/L of chloramphenicol was added to the molten agar under aseptic conditions prior to solidification. Inoculated PDA plates were incubated at 25±2°C for 5–7 days, followed by identification of the resulting fungal colonies based on their macro-morphological and micro-morphological characteristics.

Fungal Identification and Characterization:

Fungal isolates were initially identified based on macro- and micromorphological characteristics on PDA medium, then purified using the hyphal tip technique. Taxonomic classification to the species level followed established keys by Moubasher (1993) and Pitt and Hocking (1997). Molecular confirmation was performed via PCR and nucleotide sequencing at the Asco Learning Center (Baghdad). A toxigenic isolate, confirmed for mycotoxin production in animal feed, was ultimately selected for this study.

Rice Dextrose Agar (RDA):

Fungal Cultivation and Aflatoxin Production: The rice medium was prepared following the method of Abbas et al. (1984), as modified by Al-Warshan (1999), to cultivate the *A. flavus* isolate and evaluate its aflatoxin production. One kilogram of washed, cleaned rice was soaked in 125 ml of distilled water for two hours, then distributed into 250 ml glass flasks. The flasks were sterilized using an autoclave at 121 °C and 15 psi for 20 minutes over two consecutive days.

Inoculation and Processing of Rice Medium:

The rice medium was inoculated with five discs of the *A. niger* isolate and incubated at 25 ± 2 °C for two weeks, with flasks shaken every 48 hours to ensure uniform fungal growth. Following incubation, the medium was oven-dried at 45–50 °C until reaching a constant weight, then milled using an electric grinder for subsequent incorporation into poultry feed.

One-day-old broiler chicks from a private hatchery in Karbala were housed in a controlled facility for a 42-day trial, provided with ad libitum feed and water, and subjected to a standardized management and veterinary program. The chicks were divided into three treatment groups, each with three replicates, including a control group fed a basal diet and experimental groups fed a diet contaminated with 1 g/kg of mycotoxins. Following the study, liver samples were excised and fixed in 10% neutral buffered formalin for histological examination.

Experimental Treatment Combinations:

- 1- Control group without any feed additives.
- 2- Feed contaminated with the aflatoxin *A. niger* at a rate of 1g/kg of feed.
- 3- The selected chicks were fed a standard diet with the addition of aflatoxin + 1.25 g / kg of Nystatin.
- 4- The selected chicks were fed a standard feed with added aflatoxin and 5g/kg of pomace powder.
- 5- The selected chicks were fed a standard diet supplemented with aflatoxin +5g/kg of pomace powder + 1.25 g / kg Nystatin.

Histological Processing:

Tissue processing was performed at the Al-Wateen Laboratory in Karbala Governorate, following the methodology described by Luna (1968).

Results and discussions

Methodology for Isolation and Phenotypic Identification of *A. niger*:

Isolation results showed the *A. niger* pathogens on **billet** feed. **Figure (1)** "Growth of *A. niger* is rapid, reaching full maturity in 3 to 4 days. The mycelium is initially white, but the colony surface soon becomes covered with a thick layer of black conidia giving it a characteristic dark, velvety or granular texture. The fungus produces profuse, branched, and septate mycelia. Its conidia are globose, unicellular, and echinulate measuring 3.5–5 µm in diameter, and exhibit a distinct dark brown to black pigmentation (Pitt & Hocking, 2009)."

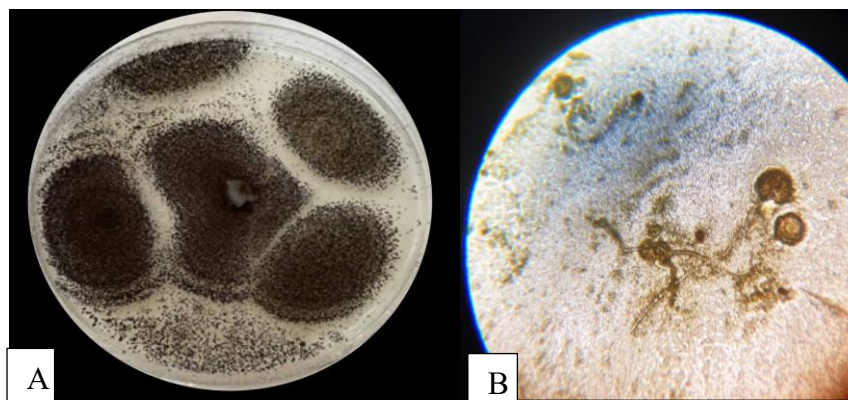


Figure 1. (A): *A. niger* colony on (PDA). (B): The sporophyte of *A. niger* is undivided, the conidiophore was unbranched and ends in a head bearing conidia in chains.

Molecular diagnosis of *A. niger*:

The molecular diagnostic approach provided a robust confirmation of the isolated strains. The emergence of 1500 bp PCR-amplified products aligns with established genomic profiles for *A. niger*, demonstrating the high sensitivity of molecular tools in detecting feed-borne pathogens

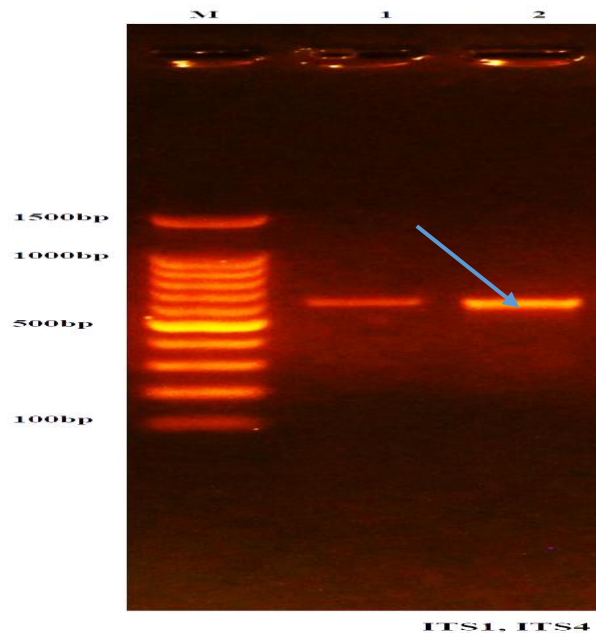


Figure 2. The resulting bands from electrophoresis and of sizes (nitrogenous base pair, pb) are fixed on left side subordinate DNA ladder.

The results of the nitrogenous base sequence analysis showed that isolate No. 2 belongs to the fungus *A. niger*

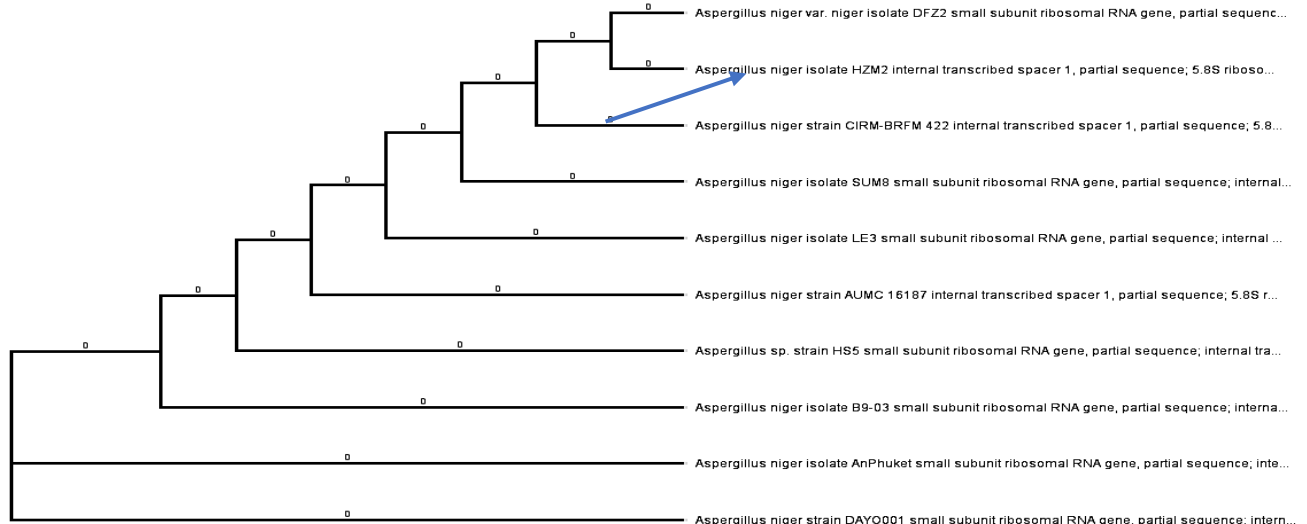


Figure 3. Phylogenetic analysis confirmed the evolutionary relationship and genetic identity of the local *A. niger* isolates relative to international accessions registered at NCBI.

The genetic kinship of the isolated fungal strains was evaluated through comprehensive DNA nucleotide sequence analysis. The resulting sequences were submitted to the GenBank database to determine their phylogenetic relationship with global strains archived in NCBI. Notably, the Iraqi isolate was officially registered under the accession number PX569964.1. Comparative analysis confirmed that the fungus identified in this study is genetically distinct from previously recorded isolates in the NCBI database, highlighting its unique genomic profile. In contrast to conventional phenotypic and morphological descriptions that may lack precision, PCR-based identification provides a more definitive approach. By targeting specific DNA sequences, this molecular technique overcomes the inaccuracies associated with traditional microscopy, delivering a rapid and highly sensitive method for fungal characterization. Advanced nucleotide sequencing has revolutionized fungal identification across diverse environments; for instance, Al-Tememe *et al.* (2019) demonstrated its efficacy in characterizing species like

Alternaria porri from apricot trees. This technology has since been successfully applied to identify pathogens in aquatic life, such as fish (Al-Hakeem *et al.*, 2023), and more recently, in poultry feed contaminants as highlighted by Al-Tememe *et al.* (2025).

The mycotoxin effect of *A. niger* on the tissues of the small intestine, of poultry is under study.

Pathological tissue changes occur as a result of treating poultry with fungal toxins under study resulted in histopathological changes in the liver representing local necrosis, vascular congestion, proliferation of inflammatory cells, and mild to severe hepatocellular degeneration (Figure 4). Compared with histological section in poultry which were treated with mycotoxin and PSP there were fewer histological alterations. The liver displayed slight hepatocellular degenerative changes compared to the Figure 4, while still present, congestion and expansion were less noticeable (Figure 5). It was found that administering Nystatin, at a concentration of 1.25g/kg, to poultry previously infected with mycotoxin resulted in histological section of liver in chicken reveal the after treatment, the liver displayed slight hepatocellular degenerative changes with fewer necrotic regions and mild congestion (Figure 6). The Nystatin 1.25g/kg + PSP to poultry previously infected with mycotoxin show the highest level of histological improvement was seen in this group. The architecture was nearly typical, with little cellular deterioration and no necrosis. (Figure 7). On the other hand, the control treatment appears finding the normal architecture and well-arranged of hepatic cord around central vein and the nucleus located centrally (Figure 8).

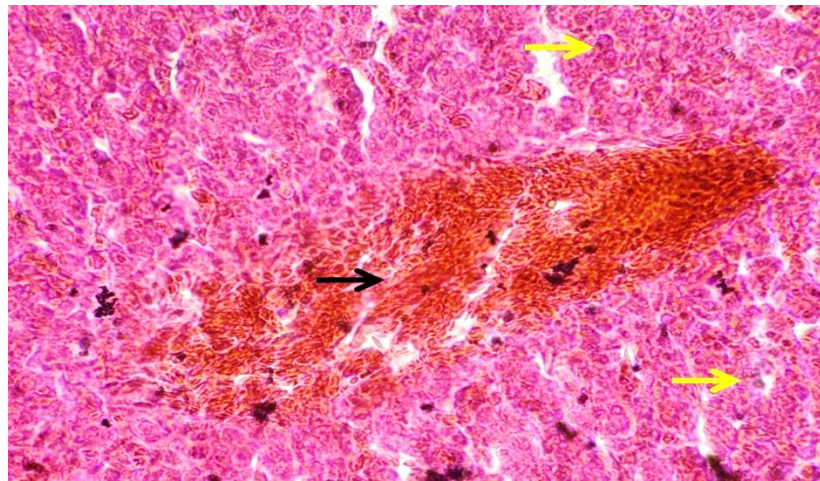


Figure 1. Photomicrography of liver in chicken show the liver displayed particular necrosis, vascular congestion, proliferation of inflammatory cells, and mild to severe hepatocellular degeneration

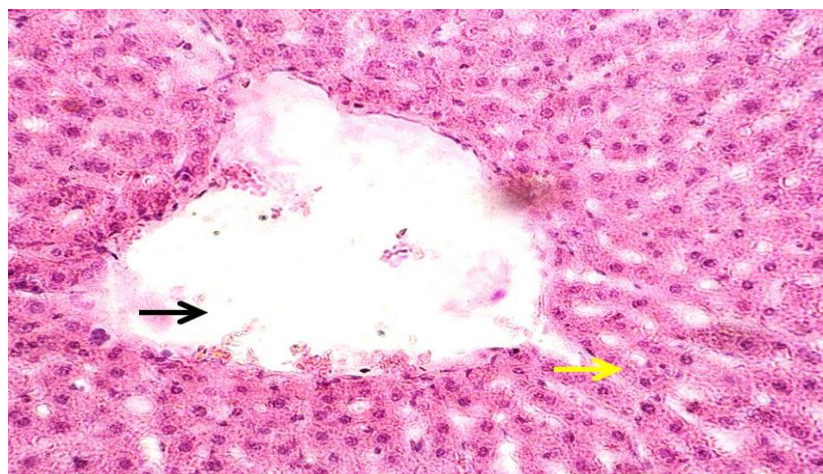


Figure 5. Photomicrography of liver in chicken there were fewer histological alterations. The liver displayed slight hepatocellular degenerative changes (yellow arrow) with fewer necrotic regions and mild congestion (black arrow).

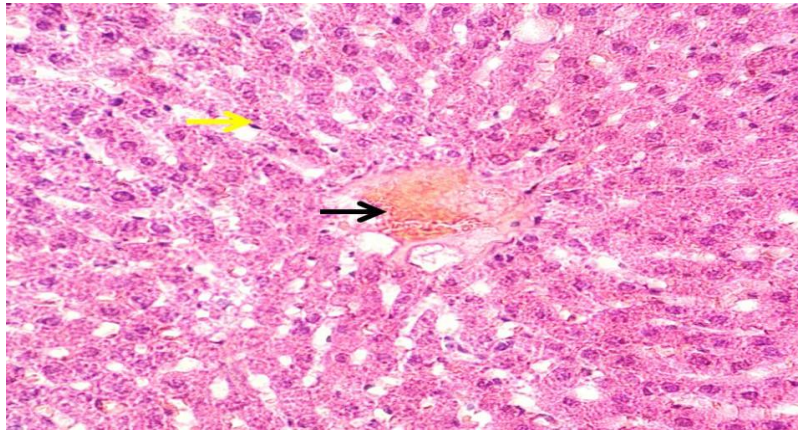


Figure 6. Photomicrography of liver in chicken show there was a discernible improvement in the histology after treatment. The liver showed minor residual alterations that were mostly restricted to perivascular regions (black arrow). H&E stain. 400X.

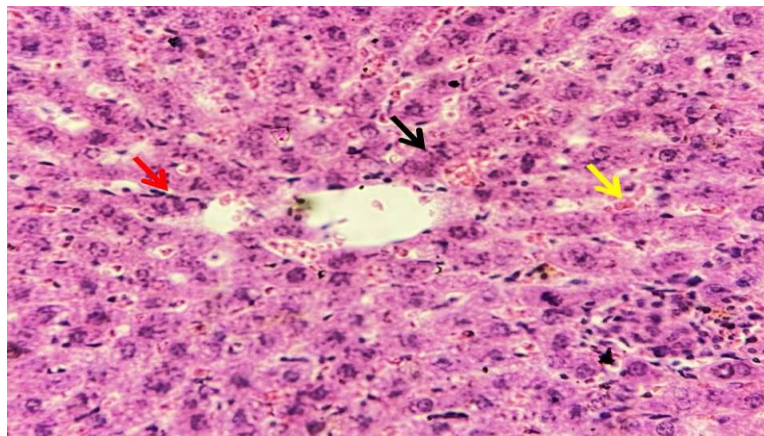


Figure 7. Photomicrography of liver in chicken show the highest level of histological improvement was seen in this group. The architecture was nearly typical, with little cellular deterioration and no necrosis. H&E stain. 400X.

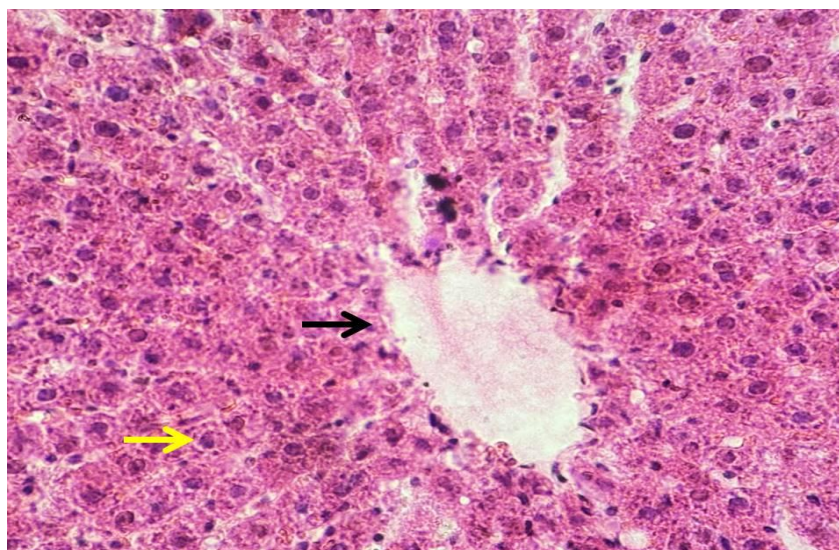


Figure 8. Photomicrography of liver in chicken (Control group) finding the normal architecture and well-arranged of hepatic cord around central vein (black arrow), and the nucleus located centrally (yellow arrow). H&E staining, 400X

The results showed that mycotoxins cause clear pathological tissue changes in the poultry liver, as the liver is one of the organs that mycotoxins primarily target, negatively affecting its efficiency and the bird's overall health. The hepatic lesions observed in this study align with the findings of Ortatali *et al.* (2005), Kumar and Balachandran (2009), Bakeer *et al.* (2013) and Kraidi *et al.* (2019). Microscopic examination revealed hepatocyte deterioration, fatty changes, and vacuolar degeneration. Additionally, these studies reported bile duct congestion, hyperplasia, and inflammatory infiltration characterized by mononuclear cells and heterophils. While, Ochratoxin A (OTA) is primarily recognized as a nephrotoxin, it significantly induces hepatic lesions. Research by Kumar *et al.* (2004), Elaroussi *et al.* (2008), and Abidin *et al.* (2011) identified mononuclear cell infiltration within the liver parenchyma, accompanied by thickening of the outer hepatic layer. Pathological changes include congestion in the portal areas and sinusoidal spaces, which often appear swollen. Prolonged exposure leads to the deterioration of hepatic cords, individual cell necrosis, and vacuolar atrophy. Furthermore, OTA induces the proliferation and subsequent degeneration of the bile duct epithelium. Supplementation with PSP mitigated the OTA-induced hepatic lesions, such as mononuclear cell infiltration and sinusoidal congestion, by enhancing the antioxidant status of the liver tissue. These findings align with the observations of Abdollahi *et al.* (2012). who reported that pomegranate seed by-products effectively modulate the hepatotoxic effects of mycotoxins by stabilizing hepatic enzyme levels and reducing inflammatory cell infiltration. The administration of Nystatin significantly improves liver health by limiting the endogenous production of toxins through its direct action on the fungal cell membrane (dos Santos *et al.*, 2017). This mechanism, which involves the alteration of membrane permeability and subsequent lysis of the protoplasts, effectively mitigates the hepatotoxic burden induced by *A. niger*. The synergistic approach of combining antifungal agents with natural antioxidants, such as PSP, effectively mitigates the histopathological damage in the liver by neutralizing reactive oxygen species while simultaneously reducing the fungal load (Valenzuela-Grijalva *et al.*, 2017). This dual mechanism enhances the regenerative capacity of hepatic tissues following exposure to *A. niger* toxins. Maybe this means that Pomegranate Seed Pomace (PSP) not only acted as an antioxidant but may also have enhanced the effectiveness of the treatment used.

Conclusions:

Mycotoxins are considered one of the most important problems and threats faced by the poultry producers. The primary therapeutic effect of PSP in mitigating *A. niger* mycotoxicosis stems from its potent antioxidant capacity. PSP acts by sequestering reactive oxygen species, thereby stabilizing hepatic membranes and reducing the inflammatory infiltrates within the liver parenchyma. This restorative action significantly lowers the severity of histopathological lesions, such as sinusoidal congestion and vacuolar atrophy, providing a robust physiological defense against mycotoxin-induced liver damage. The present study demonstrates that Nystatin effectively inhibits *A. niger* by disrupting fungal membrane permeability, thereby suppressing endogenous toxin synthesis.

Ethical Compliance

All animal procedures were approved by the Animal Ethics Committee, College of Agriculture, University of Kerbala. Ethical approval code: UOK.Aagri. No. 6.2026.

Acknowledgments

We are very proud and grateful to everyone who helped us achieve this accomplishment this research and its perfect completion.

References

1. Abdollahi, M.; Samadi, F.; Ghassemi-Nejad, J.; and Ebrahimi, P. (2012). Effect of pomegranate seed pulp and its extract on the performance, serum biochemistry and antioxidant status of broiler chickens fed with aflatoxin-contaminated diets. *Poultry Science Journal*, 1(1), 31-40.
2. Abidin, Z.; Khatoun, A. and Numan, M. (2011). Mycotoxins in broilers: pathological alterations induced by aflatoxins and ochratoxins, diagnosis and determination, treatment and control of mycotoxicosis. *Worlds Poult Sci J.* Vol. 67, 485–496.
3. Ajafar M, Al-Jebory HH, Al-Saeedi MKI (2024). Effect of in Ova injection of lysophospholipid in hatching traits, chick's quality, and chicks physical traits of broiler (Ross 308). *Adv. Anim. Vet. Sci.*, 12(7):1206-1213. <https://dx.doi.org/10.17582/journal.aavs/2024/12.7.1206.1213>.
4. Al-Hakeem, A. M., Al-Tememe, Z. A., and Abd Alssirag, M. (2023). Morphological and Molecular Identification of Fungi Associated with Zuri Fish (Pilchard sp.) in Karbala/Iraq. In *IOP Conference Series: Earth and Environmental Science* (Vol. 1158, No. 5, p. 052006). IOP Publishing.
5. Al-Jebory HH, Al-Saeedi MKI, Ajafar M, Ali NAL (2024). Impact of melatonin on improving productive traits of broiler exposed to environmental stress. *Adv. Anim. Vet. Sci.* 12(4): 775-781. <https://dx.doi.org/10.17582/journal.aavs/2024/12.4.775.781>.

6. Al-tememe, Z. A., Lahuf, A. A., Kareem, A. A., Kadhim, A. A., and AL-Mosawy, M. M. (2019). A survey and molecular identification of *Aspergillus versicolor* causing brown rot on imported spruce (*Picea canadensis*) wood in Karbala province, Iraq and control it using Copper Boron Chromate. In IOP Conference Series: Earth and Environmental Science (Vol. 388, No. 1, p. 012010). IOP Publishing
7. Al-Tememe, Z.A.M., Hamid, M.H., Al-Musodi, M.F.H. (2024). The effect of the mycotoxins of some fungi isolated from poultry feeds on the relative weight of the liver and gizzard of broiler chicks in different regions of Karbala, Iraq. *Open Veterinary Journal*, 15(2), pp. 1050–1055.
8. Al-Musodi MF., Al-Tememe,ZE and . Hamid,MH.,(2025). Effects of Administering Fungi Isolated from Poultry Feed on Some Physiological and Productive Parameters in Rose Chickens in Several Regions of the Karbala Governorate, *Journal of Animal Health and Production*.vol 13(2):393-401.
9. Arkan NB, Al-Jebory HH, Al-Khafaji FRA (2025). Impact of nano-encapsulated of anti-bacterial peptide on broiler growth performance under oxidative stress condition. *Adv. Anim. Vet. Sci.* 13(6): 1169-1179. DOI | <https://dx.doi.org/10.17582/journal.aavs/2025/13.6.1169.1179>.
10. Bakeer, A.M.; Farid, A.S. and AbdElKarim, M.F. (2013). The hepatotoxic and nephrotoxic effects of mycotoxin in broiler chickens. (*BVMJ*), 25(1), 29–45.
11. Bennett, J. W. and Klich, M. (2003). Mycotoxins. *Clinical Microbiology Reviews*, 16(3), 497-516.
12. Çam, M.and İçyer,N.C. (2015). Phenolics of pomegranate peels: extraction optimization by central composite design and alpha glucosidase inhibition potentials. *Journal of Food Sciences and Technology*. 52(3):1489-97. doi: 10.1007/s13197-013-1148-y
13. D’Mello, J. P. F. and Macdonald, A. M. (1997). Mycotoxins. *Animal Feed Science and Technology*, 69(1-3), 155-166.
14. D’Mello, J. P. F. (2000). *Farm Animal Nutrition*. CABI Publishing. Wallingford, United Kingdom . pp.438.
15. Elaroussi, M.A.; Mohamed, P.R.; Elgendy, M.S.; El Blarkouky, E.M.; Abdou, A.M. and Hatab, M.H. (2008). Ochratoxicosis in broiler chickens: functional and histological changes in targetorgans. *Int. J. Poult. Sci.* 5, 414–422.
16. FAOSTAT Database (2012). *Feeds and feeding of poultry*. Food and Agriculture Organization of the United Nations.
17. FAOSTAT Database (2021). *Animal nutrition strategies and options to reduce the use of antimicrobials in animal production*. Rome: Food and Agriculture Organization of the United Nations.
18. Ghasemi, K.; Al-Khazraji, A. K. and Al-Tae, Y. A. (2021). The Effect of Pellet Feed on Growth Performance and Feed Efficiency of Broiler Chickens. *Journal of Agricultural and Environmental Sciences*, 6(1), 55-61.
19. Huang T. H.; Peng G.; Kota, B. P.; Li, G. Q.; Yamahara ,J.; Roufogalis ,B. D.(2005). Anti-diabetic Action of Punica Granatum Flower Extract: Activation of PPAR-Gamma and Identification of an Active Component. *Toxicol. Appl. Pharmacol.* 207 (2), 160–169. 10.1016/j.taap.2004.12.009 .
20. Kandhare, V. P.; Kumar, R.; Singh, R. and Kumar, D. (2017). Aflatoxins in Poultry Feed: A Review. *Veterinary World*, 10(9), 1109-1115.
21. Kaur G.; Jabbar Z.; Athar M.; Alam ,M. S. (2006). Punica Granatum (Pomegranate) Flower Extract Possesses Potent Antioxidant Activity and Abrogates Fe-NTA Induced Hepatotoxicity in Mice. *Food Chem. Toxicol.* 44 (7), 984–993. 10.1016/j.fct.2005.12.001.
22. Kraidi, Q.A.; Abbas, S.S. and Chayan, M.A. (2019). Study of pathological changes caused by mycotoxins in broilers in Al-Qurna City, Basra, Iraq. *Plant Arch.* 19(2), 2579–2584.
23. Kumar, A.; Jindal, N.; Shukla, C.L.; Asrani R.K.; Ledoux D.R. and Rottinghaus, G.E. (2004). Pathological changes in broiler chickens fed ochratoxin A and inoculated with *Escherichia coli*. *Avian Pathol.* 33(4), 413–417. doi: 10.1080/03079450410001724021.
24. Kumar, R. and Balachandran, C. (2009). Histopathological changes in broiler chickens fed AflatoxinB1 and cyclopiazonic acid. *Vet. Arhiv.* 79, 31–40.
25. Malik, A.; Afaq, F.; Sarfaraz, S.; Adhami, V. M.; Syed, D. N. and Mukhtar,H.(2005). Pomegranate fruit juice for chemoprevention and chemotherapy of prostate cancer. *Proceedings of the National Academy of Sciences (PNAS)*. 102 (41), 14813-14818. <https://doi.org/10.1073/pnas.0505870102>
26. Moubasher, A. H. (1993). *Soil fungi in Qatar and other Arab countries*. Doha, Qatar: Scientific and Applied Research Centre, University of Qatar.
27. Negi, P. S.; Jayaprakasha, G. K.and Jena, B. S.(2003). Antioxidant and antimutagenic activities of pomegranate peel extracts. *Food Chemistry*.80(3), 393-397. [https://doi.org/10.1016/S0308-8146\(02\)00279-0](https://doi.org/10.1016/S0308-8146(02)00279-0)
28. Ortatatli, M.; Oguz, H.; Hatipogl, F. and Karaman, M. (2005). Evaluation of pathological changes in broilers during chronic aflatoxinb1 (50 and 100 ppb) and clinoptilolite exposure. *Res Vet Sci.* 78, 61–68. doi: 10.1016/j.rvsc.2004.06.006.
29. Pitt, J. I. and Hocking, A. D. (2009). *Fungi and Food Spoilage* (3rd ed.). Springer Science & Business Media.
30. Ramos, A. J.; Fink-Gremmels, J. and Hernandez, J. M. (1996). Prevention of Mycotoxicosis in Farm Animals. *Journal of Applied Toxicology*, 16(5), 369-377.
31. Salman, K.A.A, M.K.I. Al-Saeedi and H.H. Al-Jebory. 2025. Effect of adding manganese sulfate for diet on the hormonal and histological response of aged roosters exposed to heat stress. *Kufa Journal For Agricultural Sciences – 2025:17(1) : 131-141.*

32. Salman, K.A.A., Al-Saeedi, M.K.I., Al-Jebory, H.H. and Al-Jebory, R.F., 2024. Effect of neem (*Azadirachta indica*) leaf powder supplementation on some blood parameters in broiler chickens exposed to heat stress. *Punjab Univ. J. Zool.*, 39(2): 177-183. <https://dx.doi.org/10.17582/journal.pujz/2024/39.2.177.183>.
33. Stowe C. B. (2011). The Effects of Pomegranate Juice Consumption on Blood Pressure and Cardiovascular Health. *Complement. Ther. Clin. Pract.* 17 (2), 113–115. 10.1016/j.ctcp.2010.09.004.
34. Valenzuela, N.; Pinelli-Saavedra, A.; Muhlia, A.; Domínguez-Díaz, D.; Ríos, H.G. (2017). Dietary inclusion effects of phytochemicals as growth promoters in animal production. *Journal of Animal Science and Technology* 59(1). DOI: 10.1186/s40781-017-0133-9.
35. Van Someren, P. D.; Varga, J. and Samson, R. A. (1990). Diagnostic Procedures for the Identification of *Aspergillus* species. *Journal of Applied Bacteriology*, 69(3), 321-329.